

Ebstein's Anomaly

What the Nurse Caring for a Patient with a CHD Needs to Know

Lindsey Justice, DNP, RN, CPNP-AC,
Cardiac Intensive Care Unit Nurse Practitioner,
Cincinnati Children's Hospital Medical Center

Louise Callow, MSN, RN, CPNP,
Pediatric Cardiac Surgery Nurse Practitioner,
University of Michigan, CS Mott Children's Hospital

Mary Rummell, MN, RN, CPNP, CNS, FAHA,
Clinical Nurse Specialist, Pediatric Cardiology/Cardiac Services,
Oregon Health & Science University (Retired)

Andrea Frederick NP
Adult Congenital Cardiology Stanford Hospital and Clinics (Original Author)

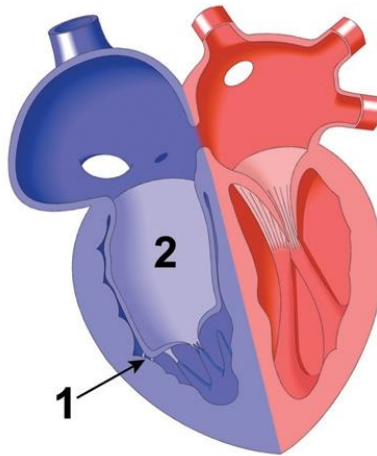
Embryology

- Formation of the normal tricuspid valve (TV) (See Defect Document on Tricuspid Valve)
 - Three leaflets, anterior, septal, and posterior, derived from the right ventricle
 - Right ventricular wall releases a layer of muscle to become valve tissue
- Abnormal process in Ebstein's anomaly
 - During 5th week of embryologic development
 - The septal and posterior leaflets remain tethered to the right ventricular muscle
 - Leaflets displaced apically

Anatomy (See illustration below)

- Wide variations
- Common with other defects (See Defect Documents for ASD, VSD, ccTGA)
 - Intracardiac defects – atrial septal defects (ASD), ventricular septal defects (VSD)
 - L-transposition of the great arteries
- Tricuspid valve leaflets
 - Septal and posterior leaflets
 - Apical displacement (Number 1 in illustration below)
 - Do not attach normally to TV annulus
 - Tips do not delamination from the RV muscle
 - Various degree of adherence of leaflets to RV wall
 - Anterior leaflet
 - Normally attached at annulus
 - Enlarged - "sail-like"
 - Often abnormally tethered to RV wall
 - May obstruct RV outlet
- Tricuspid valve orifice
 - Displaced downward into RV
 - Divides the atrium into two parts

- Normal right atrium
- ‘Atrialized right ventricle’ – inlet portion of RV - area above the displaced tricuspid leaflet (Number 2 in illustration below)
- Divides RV
 - Below valve
 - trabecular and outlet components of RV
 - Anatomical right ventricle (RV)
 - Functionally small RV cavity



Ebstein's Anomaly

Reprinted from PedHeart Resource. www.HeartPassport.com.

© Scientific Software Solutions, 2016. All rights reserved.

- Atrial septal defect (ASD)/Patent foramen ovale (PFO)
 - PFO does not close in the presence of high right atrial pressure
 - ASD present in approximately 30% of cases
- Tricuspid regurgitation (TR) of varying degrees
- Abnormal left ventricular muscular wall (non-compaction) seen in 18%

Physiology

- Hemodynamic compromise related to:
 - Severity of tricuspid regurgitation
 - Degree of RV outlet obstruction
 - Size/extent of atrialized RV chamber
 - Degree of myocardial dysfunction
 - Presence of other associated cardiac abnormalities
- Symptoms
 - Mild or absent
 - Mild displacement of TV
 - Minimal insufficiency
 - Moderate to Severe
 - Hypoxia
 - Cyanosis at rest or with exercise

- High Right Atrial (RA) pressures
 - Due to increased volume in RA
 - Results from TR
 - Increases during ventricular systole
 - Blood from atrialized RV flows back to RA
 - Open PFO – or associated ASD
 - Secondary to high RA pressure
 - Increased RA pressure
 - Results in right to left shunting at the atrial level
 - Long-term cyanosis leads to clubbing fingers/toes
 - Increased risk of paradoxical embolus
 - Exercise intolerance
 - Atrial arrhythmias secondary to accessory pathway or severe atrial dilation
 - Low cardiac output syndrome from massive RA dilation, poor RV filling and limited LV filling
 - RV function
 - Interference of RV filling by:
 - Redundant TV leaflets and insufficiency of TV
 - Abnormal contraction pattern of the atrialized portion of the RV
 - During ventricular systole, much of the blood flows back into the true right atrium rather than passing forward into the true RV
 - Dilation
 - Secondary to volume overload from TR
 - Results in arrhythmias
 - Right bundle branch block (RBBB)
 - Atrial arrhythmias
 - Electrical Conduction Disturbances (See Adult and Peds/Neo Guidelines for Arrhythmia Management)
 - Wolff Parkinson White (WPW) Syndrome seen in 20% of patients

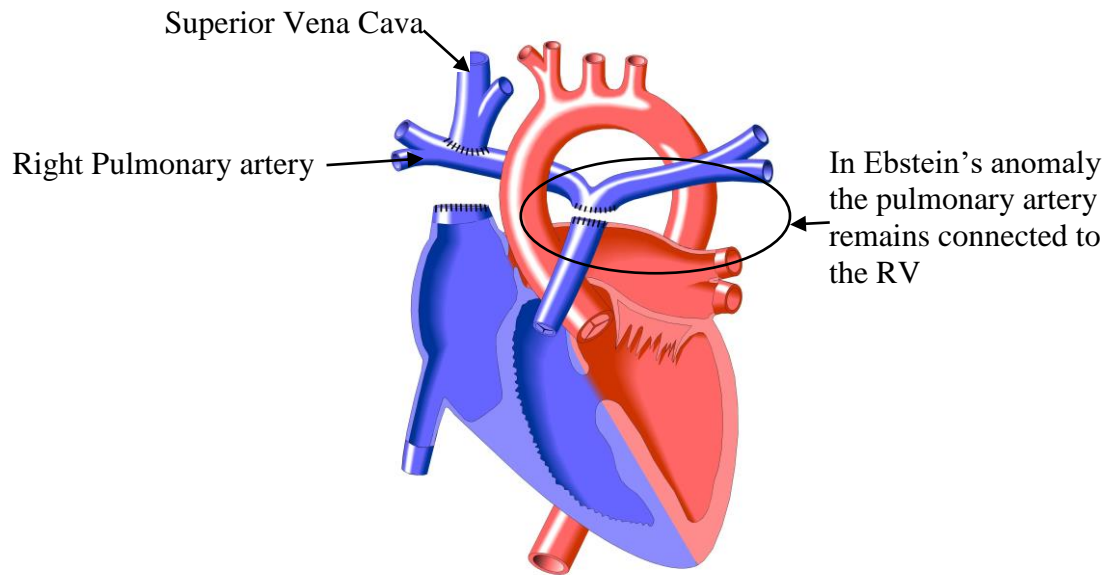
WPW syndrome is a rare congenital heart disease due to an accessory pathway between the atrium and the ventricle. Its ECG pattern is characterized by a short PR interval, a delta wave, a wide QRS complex and an abnormal ventricular repolarisation. Patients are usually asymptomatic, or have frequent paroxysmal episodes of tachycardia. These tachycardias are supraventricular tachycardias related to either reentry between the AV node and the accessory pathway, or atrial tachyarrhythmias descending through this bypass tract, or both. In the latter clinical situation, sudden cardiac death may occur in case of short refractory period within the accessory pathway. (Milliez P, Slama)
 - Atrial arrhythmias
 - Occur in 30-40% of patients
 - Atrial Flutter/Fibrillation from atrial dilation
 - Supraventricular tachycardia common
 - Tend to be recurrent and resistant to drug treatment
 - May result in sudden death if conducted to ventricle at rapid rate
 - Neonatal
 - Increased right-to-left shunt

- Increased TR
 - Due to increased pulmonary vascular resistance (PVR) and RV end-diastolic pressure
 - TR remains significant and will only improve once PVR falls
- Through foramen ovalae (FO) – ASD not always present
- May compromise flow into RV
- Will decrease pulmonary blood flow
- Increased cyanosis
 - From decreased pulmonary flow
 - Decreased cardiac output
- RV dysfunction
 - Significant portion of RV atrialized
 - Significant RV dysplasia with increased wall thickness
 - Decreased RV volume
 - Poor RV compliance
 - Decreased antegrade pulmonary blood flow
 - May require patent ductus arteriosus (PDA)
 - May require early surgical intervention

Procedures/Interventions

- Cardiac catheterization
 - Rarely done
 - Increased risk of life-threatening arrhythmias
- Surgical Repairs
 - Based on symptoms
 - Neonatal
 - Intervention depends on symptoms
 - Nursing considerations
 - Ensure that NO air enters any intravenous line due to increased right-to-left shunt
 - Monitor fluid status
 - Prevent dehydration
 - Consider hemoconcentration with increased risk of cerebral embolus – air and clot
 - Management of severe cyanosis, congestive heart failure (CHF), arrhythmias
 - Maintain patency of ductus arteriosus
 - Prostaglandin (PGE₁)
 - Nursing considerations- management side effects of PGE₁
 - Apnea
 - Hypotension
 - Hyperthermia
 - Seizures
 - Severe CHF
 - Diuresis
 - Support ventricular function

- Arrhythmia management
- Management of pulmonary blood flow and pulmonary vascular resistance
- Procedures
 - Modified Blalock-Taussig (BT) shunt
 - With pulmonary outflow obstruction
 - Single ventricle palliation (See Defect Document for Tricuspid Atresia)
 - Systemic to pulmonary artery shunt (Modified BT shunt)
 - Patch TV
 - Atrial septectomy
 - May later transition to single ventricle palliation, one-and-a-half ventricle repair, or two ventricle repair depending on TV and RV function/size/degree of regurgitation
 - If one and a half or single ventricle path will be followed by bidirectional Glenn or hemifontan operation
 - If single ventricle this is followed by completion Fontan
 - If one and a half ventricle repair, RV handles only IVC flow and if necessary a RV to PA conduit is utilized to establish continuity
 - Two ventricle repair is TV repair with assurance of RV to PA continuity and only performed when RV output is able to maintain cardiac output
 - Cardiac transplantation
- Older infants and children
 - Interventions depend on symptoms
 - Type of intervention based on age of patient at presentation
 - Procedures
 - One-and-a-half ventricle repair (See illustration below for illustration of SVC to RPA anastomosis)
 - Decrease the risk of volume stress on a marginal tricuspid valve and RV
 - Involves a bidirectional Glenn/hemiFontan connection for superior vena cava (SVC) flow to the lungs
 - Inferior vena cava (IVC) flow continues to drain into the right heart and through RV
 - ASD may be downsized or closed depending on the function of RV



Glenn Shunt in Tricuspid Atresia

Reprinted from PedHeart Resource. www.HeartPassport.com.
 © Scientific Software Solutions, 2016. All rights reserved.

- Two ventricle repair
 - Attempted in patients with enough muscular RV to maintain cardiac output
 - TV leaflets are transposed to the tricuspid annulus
 - Eliminates the atrialized ventricle
 - Minimizes TR
 - Relieves RV outflow obstruction
- Tricuspid Valve Repair/Replacement
 - Repair of TV preferable to valve replacement
 - Prosthetic valve requires anticoagulation (See Peds/Neo and Adult Guidelines for Anticoagulation Management)
 - Will need re-replacement
 - Child will outgrow prosthetic valve
 - Bio-prosthetic valves calcify and degenerate early in children
 - Additional repair depends on anatomy
 - ASD repair
 - Plication of atrialized portion of RV
- Older children and adults
 - Valve repair/replacement

- Depends on degree of regurgitation and anatomy of the valve
 - Annulus repair/reduction with valve repair
 - Valve replacement with bioprosthetic valve
 - Anticoagulation usually not needed
 - Durable in adults
 - Right Atrial reduction
 - Arrhythmia surgical management
 - Right sided ‘Maze’ procedure
 - Incisions made in RA to interrupt possible reentrant pathways that result in atrial arrhythmias including atrial fib/flutter
 - Cone procedure
 - Posterior and septal leaflets of tricuspid valve removed from annulus
 - Surgically modified and reconnected
 - Atrialized portion of RV plication to recreate new, upward placed annulus
 - Leaflets re-attached to new TR annulus
- Arrhythmia management
 - Associated with WPW and atrial tachyarrhythmias
 - Required if arrhythmia results in decreased CO
 - Medical management
 - May control arrhythmia long enough to allow neonate/child to grow
 - May still be required even after catheter or surgical ablation
 - Surgical or catheter ablation
 - May be included in planned intervention
 - Antitachycardic pacemaker may be necessary

Specific Considerations

- Neonate
 - See Physiology and Intervention sections of this document for specific care related to the neonate
 - See Ped/Neo Guidelines for the Neonate Postoperative Management, Developmental Care, Infection Prevention, Nutrition, and Pulmonary Hypertension, especially Pulmonary Hypertensive Crisis
- Postoperative care (See Pes/Neo Guidelines for Postoperative Care, Arrhythmia Management, Nutrition, and Pulmonary Hypertension)
 - Perioperative mortality between 7-20%
 - Mortality increases with severe congestive heart failure preoperatively
 - Complications include:
 - Low cardiac output
 - Sudden malignant arrhythmias

Late Complications/Routine Care (See both Peds/Neo and Adults Problem Documents on Arrhythmia Management, Anticoagulation Management, and Long-term Effects of Cyanosis)

- Follow-up Care
 - Neonatal, pediatric, and adult patients require periodic, routine follow-up

- Should be done by age appropriate pediatric and/or adult cardiologist trained in CHD at a center that provides comprehensive CHD care
- Frequency depends on complexity of defect and symptoms, at least annually
- Assessment includes monitoring of rhythm and TV and ventricular function
- Atrial arrhythmias
 - Atrial fibrillation
 - Atrial flutter
 - Supraventricular Tachycardia (SVT)
 - Sudden Death
- Valve replacement
- Congestive Heart Failure
- Cyanosis
- Paradoxical Embolus
- Endocarditis (See 2015 American Heart Association guidelines for SBE Prophylaxis for adults and children)

Management during Pregnancy

- Challenges in cardiovascular and maternal-fetal management for pregnant patient with cardiac disease
 - Physiologic changes during and after pregnancy in patients without cardiac disease
 - Changes upon the cardiovascular system
 - Increase in plasma volume by 50%
 - Increase in resting pulse by 17%
 - Increase in cardiac output by 50%
 - After delivery
 - Normalization of heart rate within 10 days
 - Return to pre-pregnancy state by 3 months
 - Stroke volume
 - Cardiac output
 - Systemic vascular resistance
 - Most women with Ebstein's Anomaly have a successful pregnancy
- Plan for pregnancy
 - Pre-pregnancy visit with ACHD trained cardiologist
 - Include partnership with cardiologist and high-risk obstetrical/fetal medicine
 - If significant maternal cyanosis may see increased risk of low birth weight and fetal loss
 - Increased risk of CHD in offspring (in the absence of a family history) to approximately 6%

References:

Attenhofer, Jost, et al. (2005). Left heart lesions in patients with Ebstein's Anomaly, *Mayo Clin Proc*, 80, 361-368.

Epstein, M. L. (2001). Ebstein's Anomaly: Congenital Stenosis and Insufficiency of the Tricuspid Valve. In H. D. Allen, E. B. Clark, H. P. Gutgesell, & D. J. Driscoll (Eds), *Moss and Adams' Heart Disease in Infants, Children' and Adolescents*, (6th ed.). Philadelphia, PA: Lippincott Williams & Wilkins.

Epstein, M. L. (2008). Tricuspid atresia, stenosis, and regurgitation. In *Moss and Adams' Heart Disease in Infants, Children, and Adolescents* (7th ed). Philadelphia, PA: Lippincott Williams & Wilkins.

Everett, A. D., & Lim, D. S. (2010). *Illustrated Field Guide to Congenital Heart Disease and Repair*. (3rd ed.) Charlottesville, VA: Scientific Software Solutions, Inc.

Franklin, W. J., Benton, M. K., & Parekh, D. R. (2011). Cardiac Disease in Pregnancy. *Texas Heart Institute Journal*, 38(2), 151–153.

Hazinski, M. F. (2013). Ebstein Malformation: Chapter 8 Cardiovascular Disorders. In M. F. Hazinski (Ed.). *Nursing Care of the Critically Ill Child* (3rd ed.). Philadelphia, PA: Elsevier.

Iung B. (2012). Heart disease in pregnant women: recent ESC guidelines. *Arch Cardiovasc Dis*, 105(2), 57-9. doi: 10.1016/j.acvd.2012.01.003. Epub 2012 Accessed online February 12, 2016.

Milliez P, Slama R. (2004). Wolff-Parkinson-White syndrome [Article in French], *Rev Prat*, 54(16), 1747-53.

Oechslin, E., Buchholz, S., Jenni, R. (2006). Ebstein's anomaly in adults: Doppler-echocardiographic evaluation, *Thorac Cardiovasc Surg*, 48(4), 209-13.

Bart, R. D., Bremner, R.M., & Starnes, V.A. (2006). Ebstein's malformation. In *Critical Heart Disease in Infants and Children* (2nd ed). Philadelphia, PA: Mosby.

Park, M. K. (2014) Part 4: Specific Congenital Heart Defects. Cyanotic Congenital Heart Disease. In M. K. Park, *Park's Pediatric Cardiology for Practitioners* (6th ed.). Philadelphia, PA: Elsevier.

Service de cardiologie, hôpital Lariboisière, 75475 Paris 10. paul.milliez@lrb.ap-hop-paris.fr

UptoDate (2010). Surgical approaches to recurrent atrial fibrillation.

Warnes, C. A., Williams, R. G., Bashore, T. M., et al. (2008). ACC/AHA 2008 Guidelines for the Management of Adults with Congenital Heart Disease: Executive Summary: a report of the American College of Cardiology/American Heart Association Task Force on Practice Guidelines. *Circulation*, 118(23), 2395-451. doi: 10.1161/CIRCULATIONAHA.108.190811. Epub 2008 Nov 7. PubMed PMID: 18997168.

Illustrations reprinted from PedHeart Resource. www.HeartPassport.com. © Scientific Software Solutions, 2016. All rights reserved.

Reviewed/revised 2016
M. Rummell